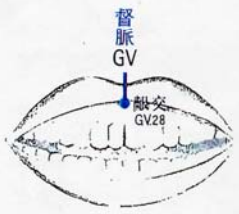
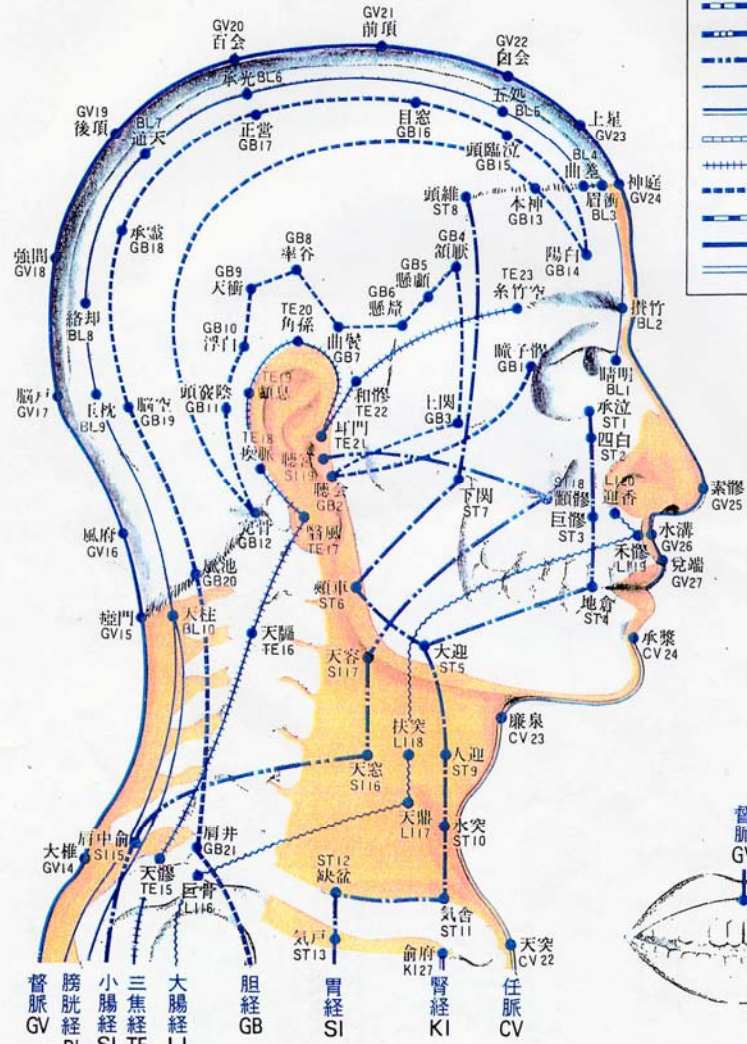


頭部側面

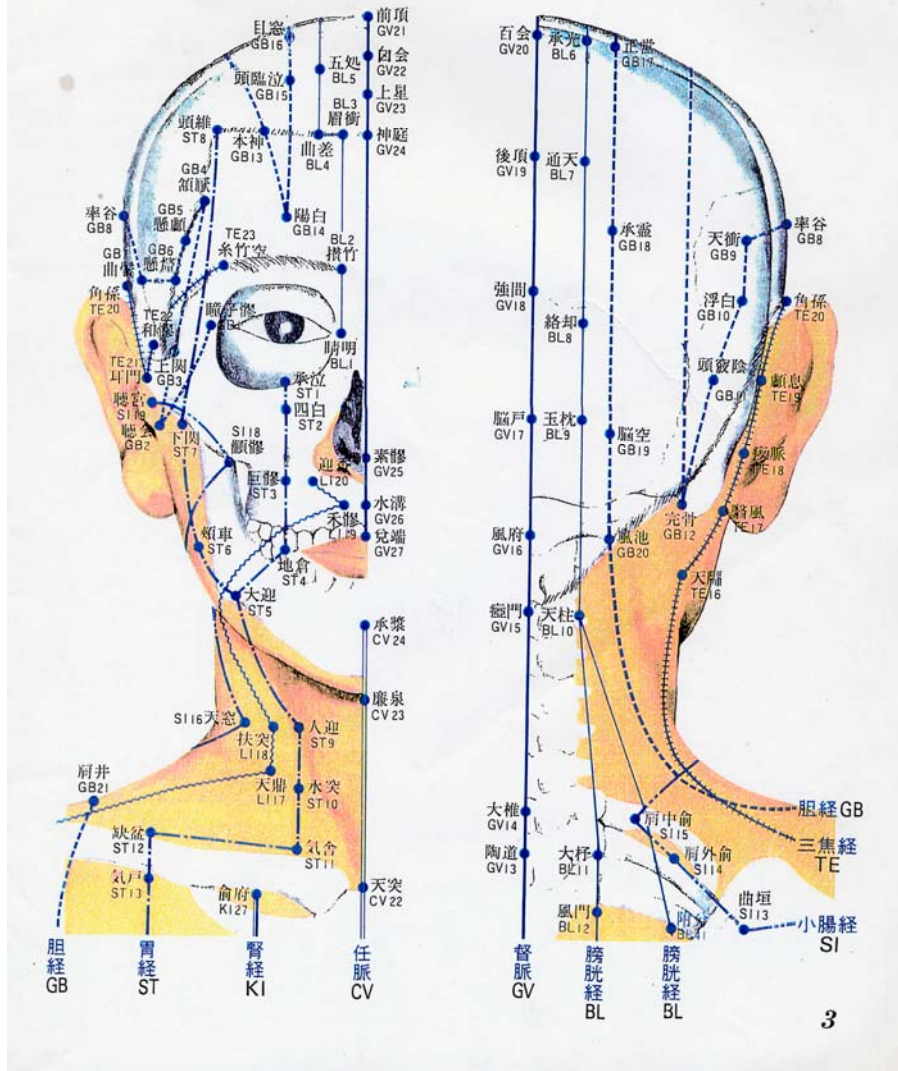
Lateral Aspect of Head

- 肺經 LU
- 大腸經 LI
- 胃經 ST
- 脾經 SP
- 心經 HT
- 小腸經 SI
- 膀胱經 BL
- 腎經 KI
- 心包經 PC
- 三焦經 TE
- 胆經 GB
- 肝經 LR
- 督脈 GV
- 任脈 CV



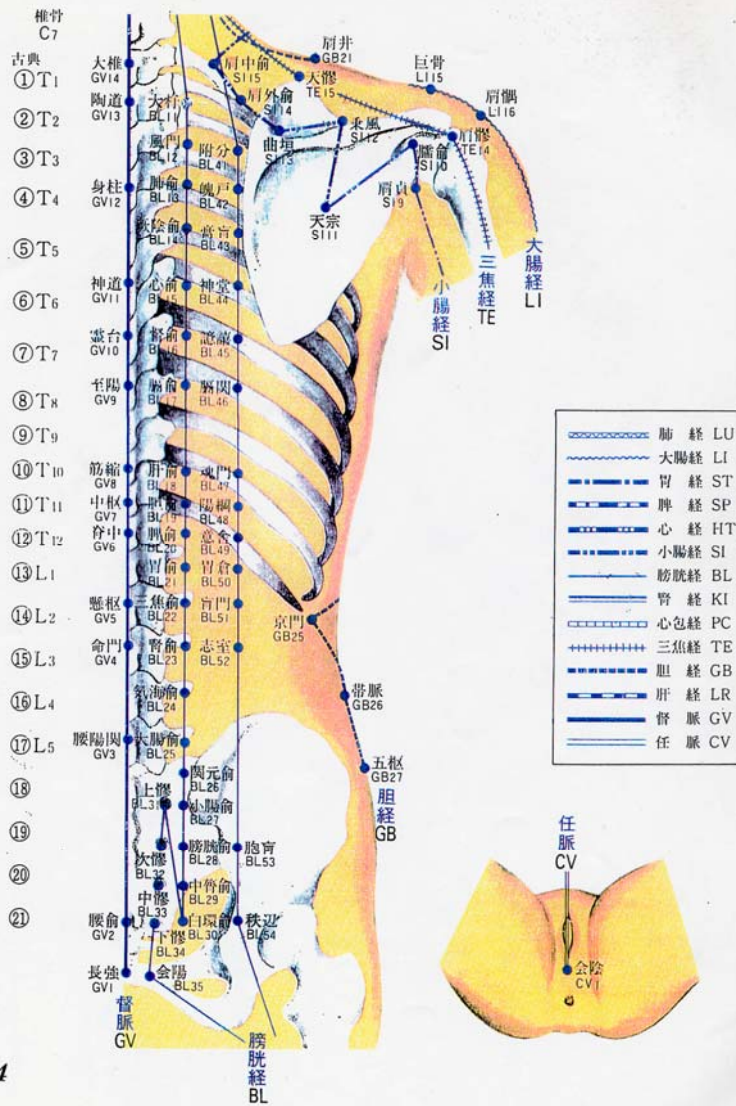
頭部前面
Anterior Aspect of Head

頭部後面
Posterior Aspect of Head

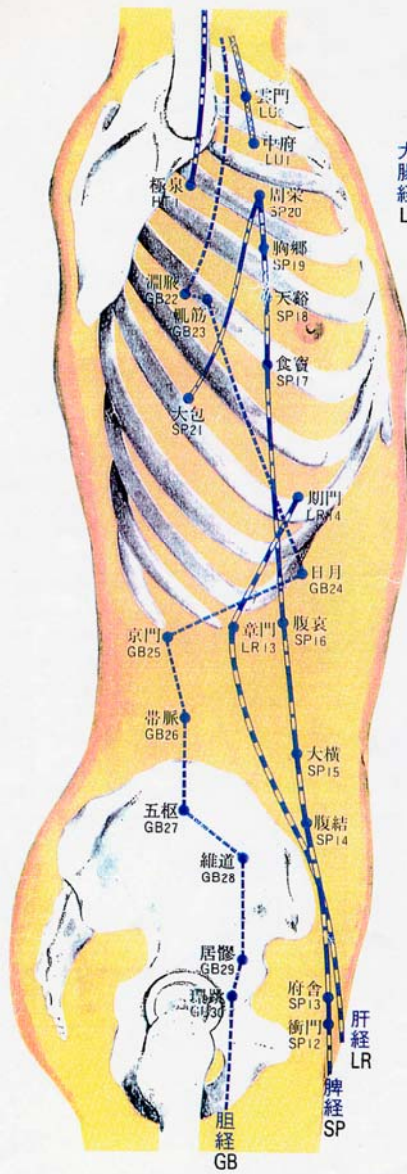


体幹後面

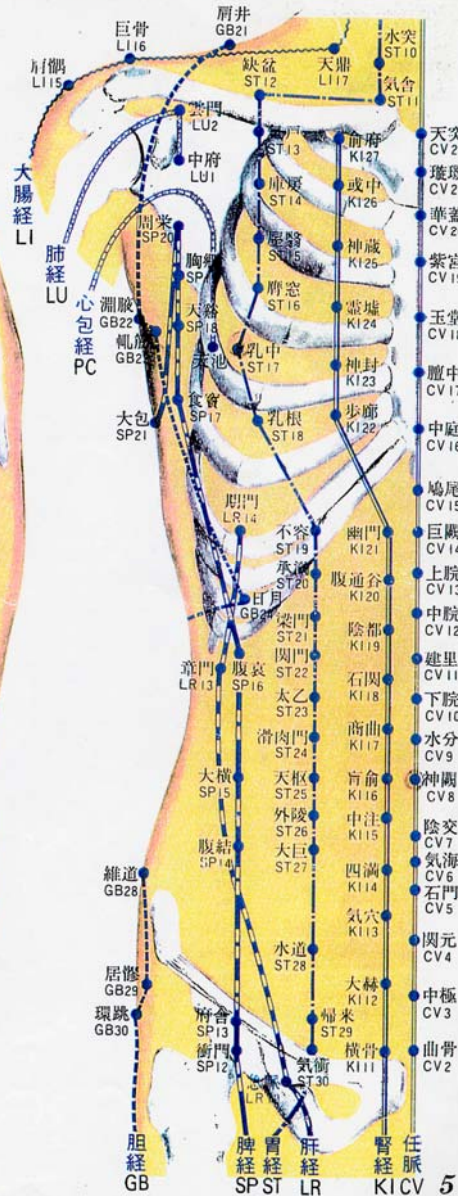
Posterior Aspect of Trunk



体幹側面
Lateral Aspect of Trunk

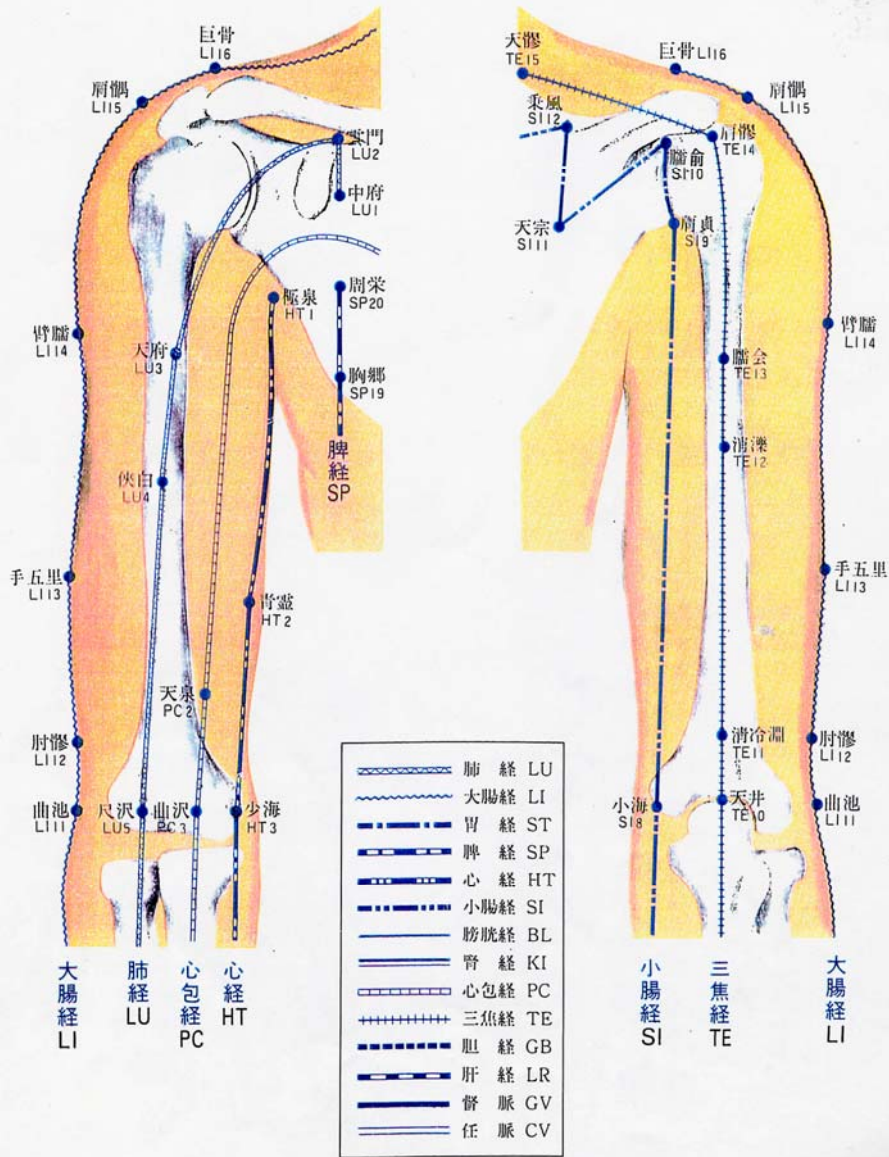


体幹前面
Anterior Aspect of Trunk

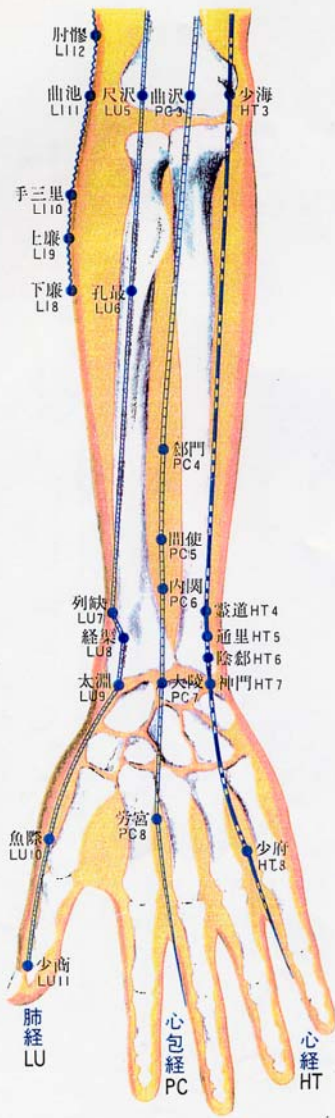


上腕前面(右)
Anterior Aspect of Rt. Upper Arm

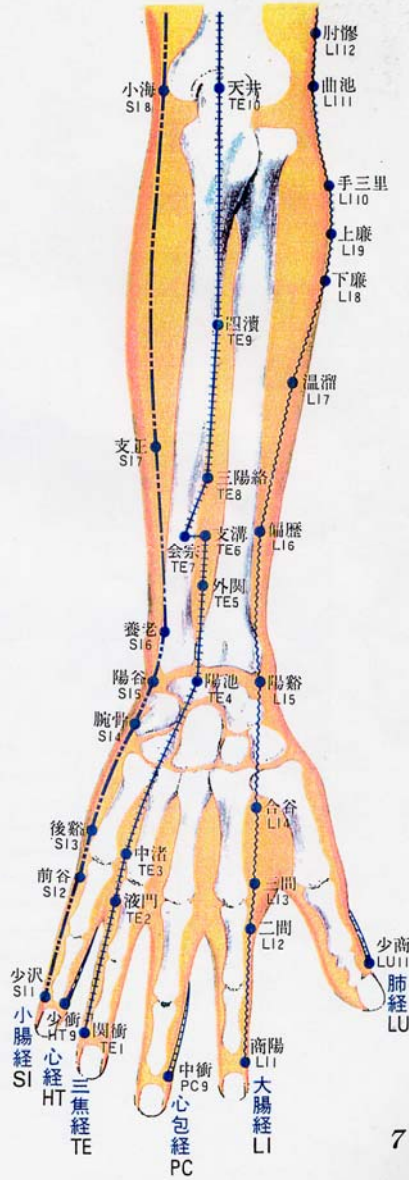
上腕後面(右)
Posterior Aspect of Rt. Upper Arm



前腕前面(右)
Anterior Aspect of Rt. Forearm

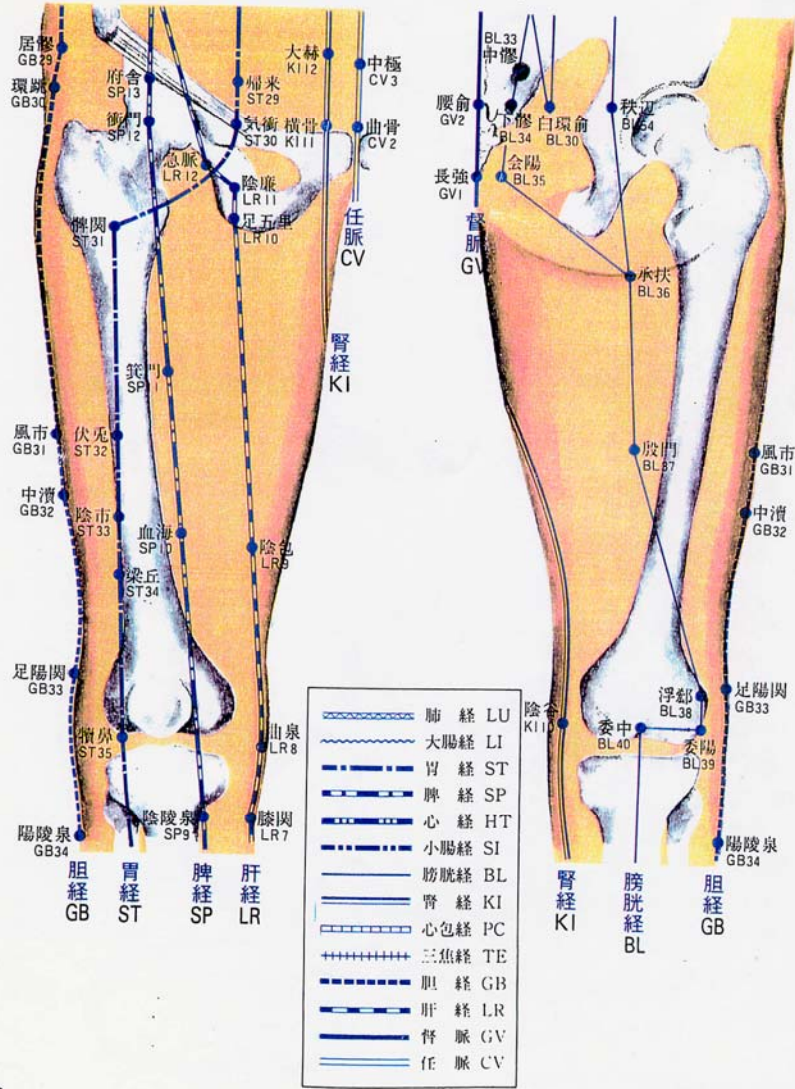


前腕後面(右)
Posterior Aspect of Rt. Forearm

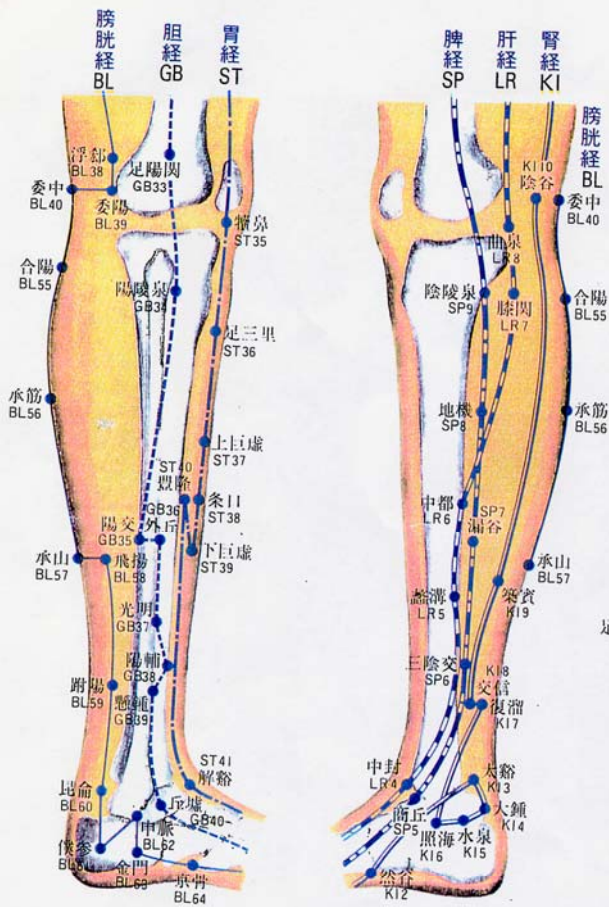


大腿前面(右)
Anterior Aspect of Rt. Upper Leg

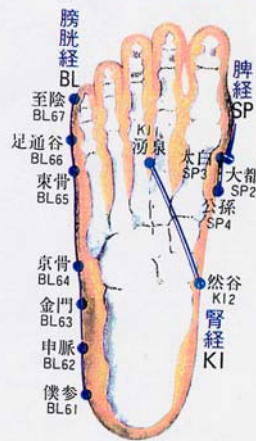
大腿後面(右)
Posterior Aspect of Rt. Upper Leg



下腿外侧(右) 下腿内侧(右)
 Lateral Aspect of Rt. Lower Leg Medial Aspect of Rt. Lower Leg



足底
 Plantar Aspect of Foot



足背
 Dorsal Aspect of Foot

